

Layered Shaving Technique for Preparation of Venous Leg Ulcers for Grafting

KHALED M. EL-RIFAIE, M.D.*; TAREK F. EL-WAKIL, M.D.** and AHMAD M. SOBHI, M.D.*

The Department of Surgery, Faculty of Medicine, Cairo University and
The National Institute of Laser Enhanced Sciences**, Cairo University.*

ABSTRACT

Venous leg ulcer (VLU) is a common problem of a significant challenge. There are many theories to explain its causes, as well as, the pathogenesis of ulcer persistence and recurrence. Skin grafting of VLU could offer a simple and cheap treatment; however, ulcer preparation for grafting has different controversial ways with different reported success rates. In the present study, layered shaving technique for VLU preparation for immediate split-thickness skin grafting was evaluated. Twenty-one patients with VLU of both sexes and at different age groups were studied. Ischaemic and diabetic leg ulcerations were excluded. Cellulitis and isolation of β -haemolytic streptococcus group A organism from the ulcers were the only indications to postpone surgery. The evaluating parameters were observed after both short and long-term follow-up. The favorable results of the present study make the layered shaving technique simple, quick and effective method for preparation of VLU for skin grafting with no significant correlation between this technique and the observed incidence of VLU recurrence.

INTRODUCTION

Chronic ulceration of the lower limb is a frequent condition, which has the prevalence of 3-5% of the general population over 65 years of age. The incidence of ulceration rises with age and especially with increase risk factors for atherosclerotic vascular occlusion. The main cause for lower limb ulceration is chronic venous insufficiency (CVI), which accounts for 80-90% of cases of leg ulceration [1].

Venous leg ulcers (VLUs) affect up to 1% of adults. VLUs remain a common problem of a significant challenge [2]. The refractory nature of VLUs affects the quality of life and work productivity of the affected patients. This, in

combination with the high costs of the long-term therapy, makes VLUs major problem especially in developing countries [3]. Many theories have been suggested to explain the causes of VLUs, but there is a little evidence to support the theory of tissue hypoxia as the main aetiological factor [4]. For many years, it was believed that disease within the deep venous system of the lower limb, such as deep vein thrombosis and post-phlebotic limb, was the main cause of VLUs. However, increasing awareness of the impact of both deep and superficial venous valvular incompetence and reflux can influence the aetiology and the healing rate of VLUs [5].

There is growing evidence, which suggested the existence of microflora at the chronic VLUs that impairs the ulcer healing process [6]. Moreover, other investigations [7,8] suggested the presence of a complex organization of the so-called fibrin cuffs around the capillaries, which offer a protection against the associated high venous pressure but unfortunately at the same time inhibit the angiogenesis process and consequently interfere with the healing of VLUs.

Most VLUs will respond to the conventional treatment, which focuses on improving regional haemodynamics. This treatment, however, often fails to heal large and recurrent VLUs especially when severe lipodermatosclerosis (LDS) is present [9]. Successful treatment of VLUs includes local wound treatment and ambulatory haemodynamic support. Compression bandaging reduces and eliminates oedema and a moist wound environment not only debrides necrotic tissue but also helps for the development of

granulation tissue, a prerequisite for epidermal repair [10].

Skin grafting could be used for the treatment of VLUs. It is a simple and cheap method. However, VLUs associated with severe LDS may require replacement of the surrounding LDS with healthy tissue. Previously [11], radical excision of the ulcer before grafting was recommended on the assumption that such a procedure would remove incompetent perforators. However, others [12-14], suggested the shaving therapy for the treatment of non-healed VLUs. This method could be used alone or prior to skin grafting for ulcer coverage.

A more conservative treatment for VLUs is to graft them after a period of topical care aiming at controlling bacterial microflora and improving the quality of granulation. This topical ulcer care remains an unsolved problem. Antibacterials, desloughing agents and dextranomer beads have been used popularly from time to time but of no hard evidence of their efficacy. The biological dressings are believed to stimulate new vessel formation and decrease the overall bacterial count [15]. However, the time needed to prepare the unhealthy ulcer bed remains unacceptably long especially with the existence of LDS with refractory VLUs. Often there is only a partial take of the skin graft, which necessitates further grafting and adds to the patient's morbidity and prolongs the hospital stay.

This controversy about the optimum method for ulcer preparation for grafting made this subject interesting to evaluate a minimally invasive procedure for ulcer preparation. The aim of the present study is to evaluate the short and long-term results of the layered shaving technique for the preparation of persistent, multiple, large circumferential and recurrent VLUs for grafting.

PATIENTS AND METHODS

Patients' criteria:

Twenty-one patients (12 females, 57.14% and 9 males, 42.86%) with clinically diagnosed VLUs were referred for split-thickness skin grafting after failure of conservative treatment to heal those ulcers. The age of the patients ranged from 46 to 74 years old with a mean of 63.04 ± 6.95 years. Due to the advanced age of

the majority of our patients, many patients of them had other associated conditions, which could have affected the condition of the leg circulation. However, leg ulcers of clear ischaemic and diabetic origins were carefully excluded from the present study. This was achieved through routine preoperative fasting and two hours postprandial blood glucose levels, as well as, by assessing the ankle/brachial pressure ratio, which must be more than 0.85.

Ten of the studied patients (47.62%) had previous ligation procedures for incompetent perforators. Multiple and/or bilateral VLUs were found in eleven patients (52.38%). The total number of the ulcers treated was 42 ulcers. There were three circumferential ulcers and nine recurrent ulcers. The ulcer size ranged from 30 to 176 cm² with a mean of 77.85 ± 21.64 cm². The duration of ulceration ranged from 4 to 14 years with a mean of 8.30 ± 2.52 years.

Technique:

Ulcers were shaved regardless of their clinical and bacteriological states. However, clinically diagnosed acute cellulitis and isolated β -haemolytic streptococcus group A organism from the ulcers were the only indications to postpone surgery [12]. Acute cellulitis was diagnosed in three patients (14.29%). Granulation tissue and other products that interfere against healing including LDS were shaved off in thin layers until a healthy base was reached.

In the theatre, the ulcerated leg was prepared by povidone iodine and the surrounding skin was descaled. All ulcers were shaved under general anaesthesia. Shaving was carried out by using the skin grafting knife by the same setting that usually used for taking a medium-thickness skin grafts. The ulcer bed, edges and margins of the surrounding unhealthy skin were shaved in layers to leave a smooth and surgically clean base. Three to four shaves are usually necessary to reach this goal. In the presence of multiple adjacent ulcers, the whole area is shaved producing a confluent base. Usually, the bleeding was only of capillary ooze, which can be controlled by wet compresses. However, a tourniquet may be used to minimize blood loss especially when shaving is extensive like that for circumferential ulcers.

The procedure ended with immediate application of generous sheets of meshed medium-

thickness skin grafts to the shaved areas. Grafts were not sutured but only overlapped over the surrounding skin. Attention for the upside down error of the grafts' position must be paid. Firm pressure with crepe bandages was applied over a tulle gras dressing, gauze and cotton wool.

Postoperative dressings were applied in 48 hours for graft inspection and for trimming of the excess skin. Then, grafts were left exposed, but dressings may be re-applied only for the circumferential grafts. Providing the graft-take has been satisfactory, gradual mobilization with firm toes to knees support began at 7-10 days after surgery and was completed in a further 3-4 days.

The overall duration of the hospital stay, as well as, the complete ulcer healing on discharge from hospital were the parameters used to assess the results of the present study. The effectiveness of the shaving technique was compared with the topical treatment with Eusol and paraffin followed by autografting. The evaluations of the shaving procedure were classified into short-term evaluation three months after the surgery, as well as, long-term evaluation 1-2 years after the surgery.

RESULTS

The mean preoperative hospital stay was 2.5 days. This preoperative period could have come down to 1.5 days only after exclusion of those three patients whose surgical intervention was postponed due to the presence of acute cellulitis. Moreover, the mean postoperative hospital stay was 15.5 days including the day of the surgery. Delayed healing of the donor sites of the split-thickness skin grafts prolonged the postoperative hospital stay by a mean of 2 days. Table (1), showed the overall preoperative and postoperative hospital stay periods.

All patients except only two (9.52%) had their ulcers healed after the first surgical intervention. In those two patients, a second surgical intervention was necessary after partial loss of the split-thickness skin graft. The overall mean surgical time was found to be 30 minutes for each patient.

Regarding the short-term results, the observed mean value of the overall rate of healing was

found to be 76% for VLUs of primary deep vein incompetence and only 62% for ulcers of the postphlebotic limb syndrome.

Regarding the long-term results, the observed mean value of the overall rate of healing was found to be 88%. Out of nine VLU patients, with an average follow up period of up to 2 years, seven patients had complete ulcer healing, while the other two patients had only small superficial ulceration within the transplanted areas. Moreover, out of the rest twelve VLU patients, with an average follow up period of up to 1 year, eleven patients had complete ulcer healing, while only one patient had a small recurrent superficial ulcer. The recurrent VLUs showed a reduction in their size by 75-85%. Finally, the observed mean value of hypaesthesia at the transplanted areas was 33%. Figs (1 & 2) represent clinical cases of the present technique.

Table (1): The overall duration of the hospital stay.

Hospital stay	Mean (days)
Preoperative	2.5 (1.5**)
Postoperative*	15.5 (17.5***)
Total	18.0

* Including the day of the surgery.

** Preoperative hospital stay after exclusion of those 3 patients with acute cellulitis.

*** Postoperative hospital stay including those patients with delayed healing of the donor site of the split-thickness skin grafts.

DISCUSSION

After a prolonged period of conservative treatment on both inpatient and outpatient basis, a group of patients with resistant VLUs are still candidates for skin grafting [10]. Direct grafting on ulcer granulation tissue after adequate ulcer preparation is a common practice in most surgical units. Ulcer preparation is targeted to diminish the overall bacterial count and to improve the quality of the granulation tissue for better chance of graft-take [16].

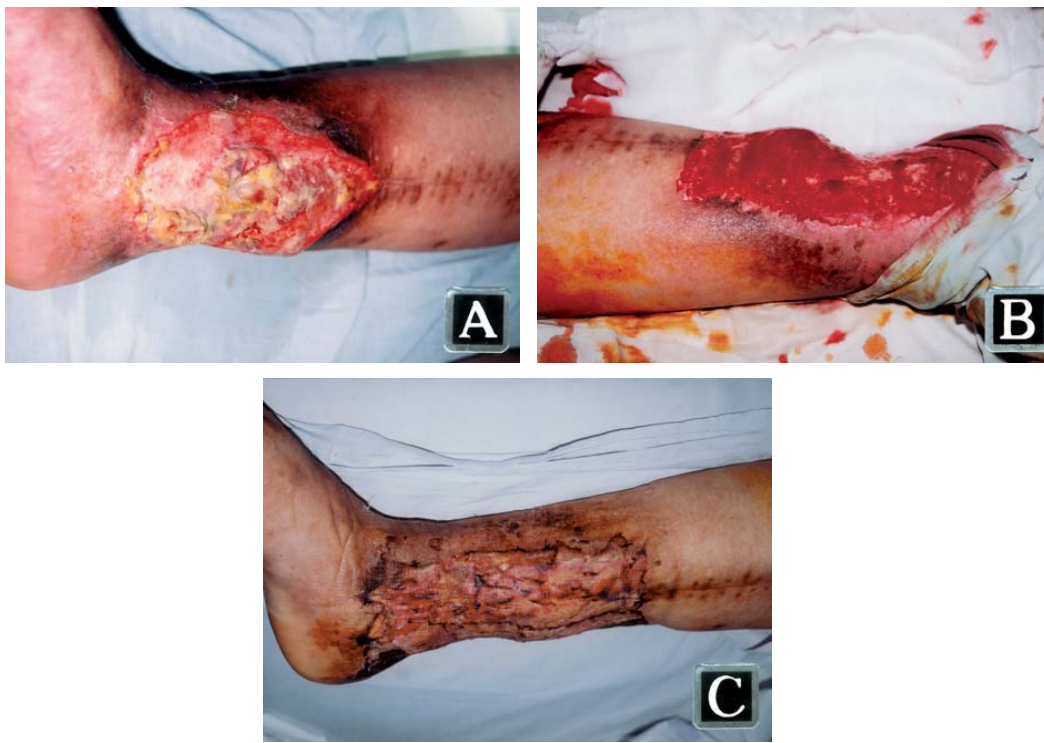


Fig. (1): Sixty-five years old male patient with recurrent venous leg ulcer of eight years' ulcer duration. (A) Preoperative appearance of the ulcer. (B) Intra-operative appearance of the ulcer immediately after layered shaving technique. (C) Complete healing of the ulcer after single application of split-thickness skin graft, 1 month after surgery.

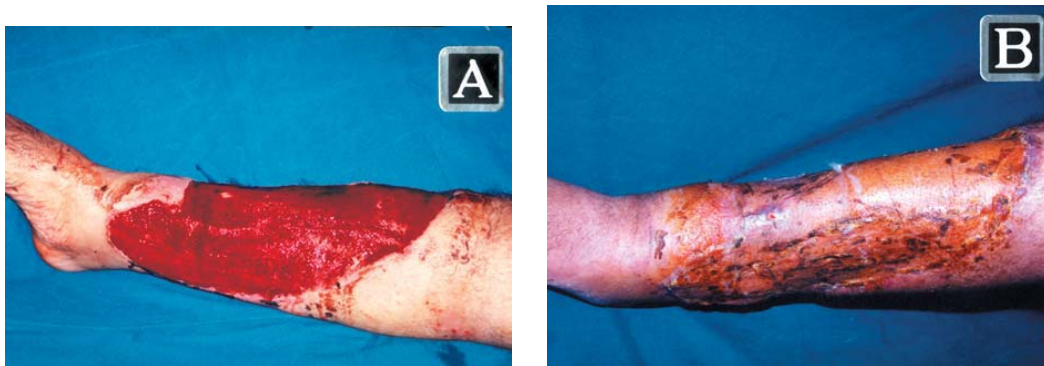

Fig. (2): Forty-eight years old male patient with venous leg ulcer of four years' ulcer duration. (A) Intraoperative appearance of the ulcer immediately after layered shaving technique. (B) Complete healing of the ulcer after single application of split-thickness skin graft, 1 year after surgery.

All VLUs are usually contaminated by mixed bacterial microflora. Although bacterial contamination plays a little or has no role in the VLUs aetiology, yet successful graft-take depends on the control of the tissue level of bacteria, irrespective to the clinical appearance of the ulcer per se, which is deceiving [6]. Although routine swab does not appear to be indicated, as it bears no clinical consequence [17], yet in the present study, routine preoperative swabs of VLUs were done only to exclude the possibility of *Staphylococcus aureus* group A infection. Diminishing the bacterial count could be established through many controversial time-consuming procedures. Antibacterials, Dextranomer beads [18] and various biological membranes [19] have been tried with different reported success rates. Biological membranes have an angiogenic effect to improve the quality of ulcer granulation, but unfortunately are time consuming and difficult during preparation, storage and maintenance. Despite the adequate methods for proper ulcer preparation, partial or complete graft loss is not uncommon, which leads into prolonged morbidity and hospital stay [12].

Wide excision of VLUs down to and including the deep fascia was previously done before immediate or delayed grafting. This was the rationale in order to interrupt the incompetent perforators, which had been blamed for ulcer recurrence. However, this procedure can prolong the morbidity and the hospital stay. So, that, it is difficult to be justified since the role of incompetent perforators in VLUs pathogenesis has been questioned. This debate was proved through many investigations. Few researchers [20] reported that neither the duration of the preoperative ulcer preparation nor the nature of the surgery appeared to affect the success or failure of the treatment. Others [21] reported a surprising finding that ligation of incompetent perforators in the presence of damaged deep veins did not prevent the development of further leg ulceration. They concluded that incompetent perforators, like venous leg ulceration, is a result of deep vein dysfunction rather than a cause of VLUs. Consequently, they suggested that elimination of perforators through wide local excision of VLUs aiming to prevent recurrence seems to be unjustifiable. It would appear that relief of obstruction and/or replacement of the diseased valves of the deep venous system instead are the only way to prevent VLU recurrence [22].

Until effective treatment of the underlying condition can be available, a group of VLUs patients are still resistant to the conservative treatment and will continue to benefit from grafting. Those patients may remain free of ulceration for a reasonable period of time provided that they are willing to co-operate postoperatively with the suggested measures designed to keep venous hypertension under control such as by limb elevation and elastic bandaging [23]. In this patient's group, a simple and practical way for complete ulcer healing within a reasonable short period of time must be used. The technique described in the present study can fulfil these requirements. It can significantly reduce both the morbidity and hospital stay periods. The trial to compare the effectiveness of the layered shaving technique with that of the topical application of Eusol and paraffin followed by autografting was not found to be justified. Continuation of the trial on that basis was found to spend for three weeks longer than those treated by the layered shaving method.

By layered shaving technique for preparation of VLUs for grafting, the bulk of bacterial microflora, unhealthy capillaries and tissue debris were removed instantly [12-14]. Most of the patients in the present study had their VLUs shaved within 2.5 days of hospital admission irrespective of the clinical and the bacteriological state of the granulation tissue after exclusion of the possibility of diabetic and ischaemic leg ulceration. Cellulitis and/or isolation of *Staphylococcus aureus* group A were the only indications to postpone surgery. The layered shaving technique is best carried out under general anaesthesia or under a regional block, as local infiltration anaesthesia was found to be unsatisfactory.

The overall hospital stay in the present study was markedly shorter than the reported results of other lines of conservative measures for VLUs preparation [12], which was 41 days for ulcer preparation by Eusol and paraffin and 29 days for the lyophilized allograft. This, in combination to the favorable short intraoperative period, as well as, the favorable short and long-term postoperative results of the present study make layered shaving technique a simple, quick and effective method for preparation of VLUs for grafting in deep venous insufficiency and/or post-thrombosis. These favorable results of the

present study agreed with that previously reported [12-14]. Moreover, the diminishing of pain at the shaved and grafted VLUs in the present study, as well as, the decrease of the ulcer size of the recurrent ulcers encourage for establishment of this technique for preparation of VLUs for grafting.

Complete and consistent skin graft-take in an area of disturbed microcirculation can be attributed to many factors. The most important factors are the debulking of the microflora and the use of atraumatic technique [10,12]. In layered shaving technique, the granulation tissue is not scraped away bluntly, but rather shaved sharply by skin graft knife leaving no devitalized tags behind. The use of skin graft knife for layered shaving was primarily described [24] for the treatment of radiodermatitis with further ongoing investigations [25,26] for early removal of dead tissue in partial thickness burns and for shaving of healed venous ulcers in preparation for dermal overgrafting. Moreover, the avoidance of diathermy during bleeding control and ligatures for graft fixation would prevent the internal debriement of the leukocytic phagocytic reserves. This observation maintains their capacity for bacterial phagocytosis for the potentially contaminated area even after shaving. These ideas globally could explain the better graft-take after ulcer preparation by layered shaving technique in the present study.

Immediate grafting is mandatory to avoid the formation of superficial sloughs. Without sutures, grafts stick firmly to the shaved base and accidental displacement could be avoided by careful application of dressings of large single sheet whenever possible with generous overlapping at the junctions with the periphery. The application of tight bandaging is very effective measure against postoperative haematomata, which usually not discovered on the first dressing. Usually no attempt was done to evacuate small postoperative haematomata, as they do not result in graft loss. Finally, meticulous attentions must be paid to secure the complete graft-take as small defects grow into recurrence very quickly.

Conclusion:

Successful treatment of VLUs includes local wound treatment modalities and ambulatory haemodynamic support to control the underlying disease. For patients with resistant VLUs, layered

shaving technique could offer a simple, quick and effective method for ulcer preparation for skin grafting with favorable short and long-term results. It has no significant correlation with the observed incidence of recurrence. It does not reduce the pathological venous refluxes and hence, continuous compression of the lower leg is important.

REFERENCES

- 1- Mekkes J.R., Loots M.A., Van Der Wal A.C. and Bos J.D.: Causes, investigations and treatment of leg ulceration. *Br. J. Dermatol.*, 148 (3): 388-401, 2003.
- 2- Padberg F.Jr., Cerviera J.J., Lal B.K., Pappas P.J., Varma S. and Hobson R.W. 2nd: Does severe venous insufficiency have different etiology in the morbidly obese? Is it venous?. *J. Vasc. Surg.*, 37 (1): 79-85, 2003.
- 3- De Araujo T., Valencia I., Federman D.G. and Kirsner R.S.: Managing the patient with venous ulcers. *Ann. Intern. Med.*, 138 (4): 326-334, 2003.
- 4- Coleridge S.P.D.: Deleterious effects of white cells in the course of skin damage in CVI. *Int. Angiol.*, 21 (2 Suppl. 1): 26-32, 2002.
- 5- Vowden K. and Vowden P.: Anatomy, physiology and venous ulceration. *J. Wound Care*, 7 (7): 1-5, 1998.
- 6- Hill K.E., Davies C.E., Wilson M.J., Stephens P., Harding K.G. and Thomas D.W.: Molecular analysis of the microflora in chronic venous leg ulceration. *J. Med. Microbiol.*, 52 (4): 365-369, 2003.
- 7- Herrick S.E., Sloan P., McGurk M., Freak L., McCollum C.N. and Ferguson M.W.: Sequential changes in histologic pattern and extracellular matrix deposition during the healing of chronic venous ulcers. *Am. J. Pathol.*, 141 (5): 1085-1095, 1992.
- 8- Drinkwater S.L., Smith A., Sawyer B.M. and Burnand K.G.: Effect of venous ulcer exudates on angiogenesis in vitro. *Br. J. Surg.*, 89 (6): 709-713, 2002.
- 9- Kumins N.H., Weinzeig N. and Schuler J.J.: Free tissue transfer provides durable treatment for large nonhealing venous ulcers. *J. Vasc. Surg.*, 32 (5): 848-854, 2000.
- 10- Burton C.S.: Venous ulcers. *Am. J. Surg.*, 167 (1): 37-40, 1994.
- 11- Pontén B.: Plastic surgery treatment of chronic venous ulcers of the leg. *Scand. J. Plast. Reconstr. Surg.*, 6: 74-79, 1972.
- 12- Quaba A.A., McDowall R.A.W. and Hackett M.E.J.: Layered shaving of venous leg ulcers. *Br. J. Plast. Surg.*, 40: 68-72, 1987.
- 13- Schmeller W., Gabr Y. and Gehl H.B.: Shave therapy is a simple, effective treatment of persistent venous leg ulcers. *J. Am. Acad. Dermatol.*, 39 (2): 232-238, 1998.

- 14- Schmeller W. and Gaber Y.: Surgical removal of ulcer and lipodermatosclerosis followed by split-skin grafting (shave therapy) yields good long-term results in non-healing venous leg ulcers. *Acta. Derm. Venereol.*, 80 (4): 267-271, 2000.
- 15- Matthews R.N., Bennett J. and Faulk W.P.: Wound healing using amniotic membranes. *Br. J. Plast. Surg.*, 34: 76-80, 1981.
- 16- Puonti H. and Asko-Seljavaara S.: Excision and skin grafting of leg ulcers. *Ann. Chir. Gynaecol.*, 87 (3): 219-223, 1998.
- 17- Schmidt K., Debus E.S., St Jesseberger, Zeigler U. and Thiede A.: Bacterial population of chronic crural ulcers: is there a difference between the diabetic, venous and the arterial ulcer? *Vasa*, 29 (1): 62-70, 2000.
- 18- Frank D.H., Robson M.C. and Heggens J.P.: Evaluation of debrisan as a treatment for leg ulcers. *Ann. Plast. Surg.*, 3: 395-399, 1979.
- 19- Teh B.T.: Why do skin grafts fail?. *Plast. Reconstr. Surg.*, 63: 323-327, 1979.
- 20- Trier W.C., Peacock E.E. Jr. and Madden J.W.: Studies on the effectiveness of surgical management of chronic leg ulcers. *Plast. Reconstr. Surg.*, 45: 20-25, 1970.
- 21- Iafrati M.D., Pare G.J., O'Donnell T.F. and Estes J.: Is the nihilistic approach to surgical reduction of superficial and perforator vein incompetence for venous ulcer justified?. *J. Vasc. Surg.*, 36 (6): 1167-1174, 2002.
- 22- Bergan J.J., Flinn W.R. and Yao J.S.T.: Venous reconstructive surgery. *Surg. Clin. North Am.*, 62: 399-408, 1982.
- 23- Bello M., Naik J., Scriven M.J., Hartshorne T. and London N.J.: The clinical management and outcome of venous ulcers in legs with deep venous obstruction. *Eur. J. Vasc. Endovasc. Surg.*, 19 (1): 62-64, 2000.
- 24- Hynes W.: Shaving in plastic surgery with special reference to the treatment of chronic radiodermatitis. *Br. J. Plast. Surg.*, 12: 43-48, 1959.
- 25- Janzckovic Z.: A new concept in the early excision and immediate grafting of burns. *J. Trauma*, 10: 1103-1108, 1970.
- 26- Thompson N. and Ell P.J.: Dermal overgrafting in the treatment of venous stasis ulcers. *Plast. Reconstr. Surg.*, 45: 20-26, 1970.